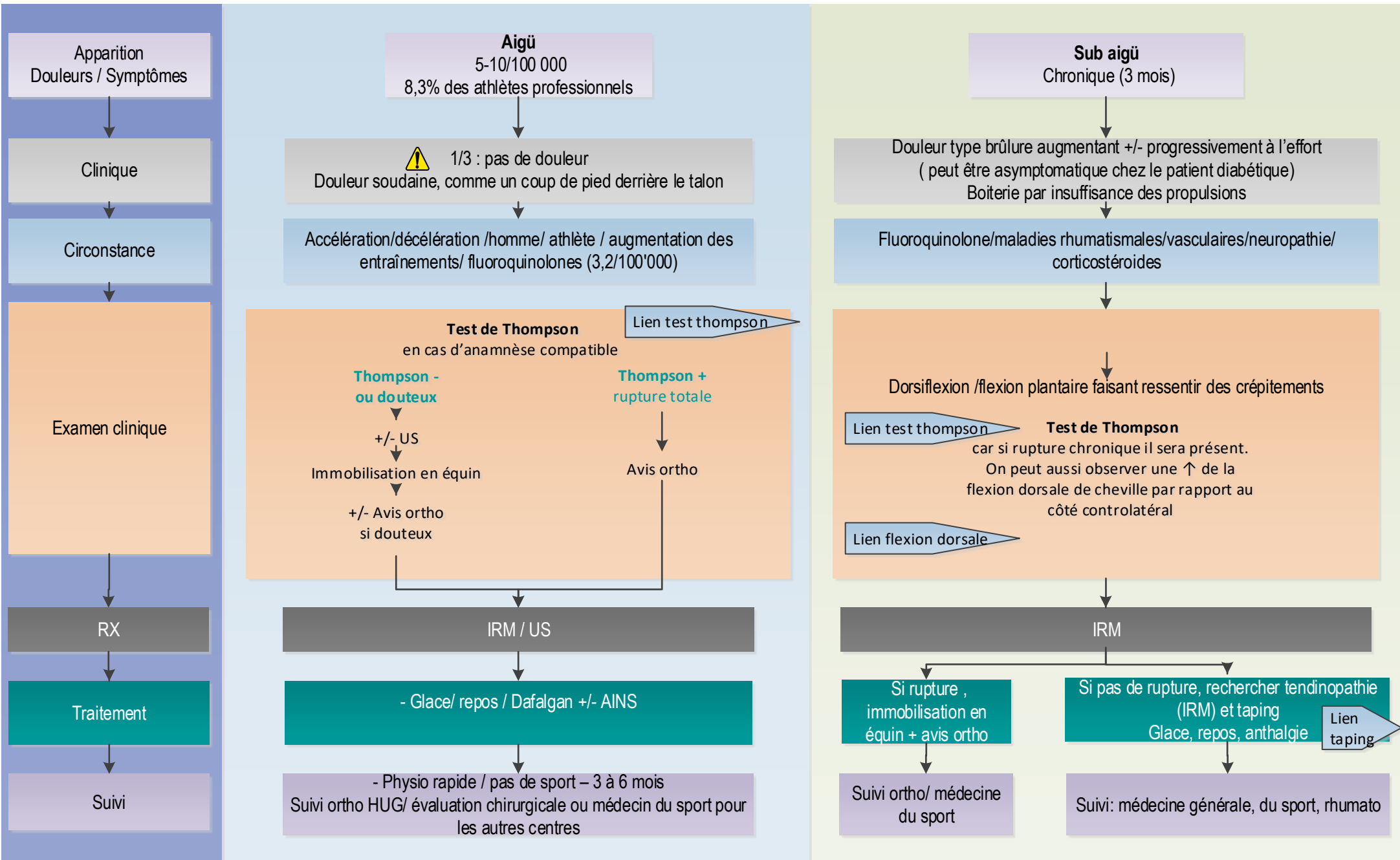


# SUSPICION DE RUPTURE TENDON D'ACHILLE

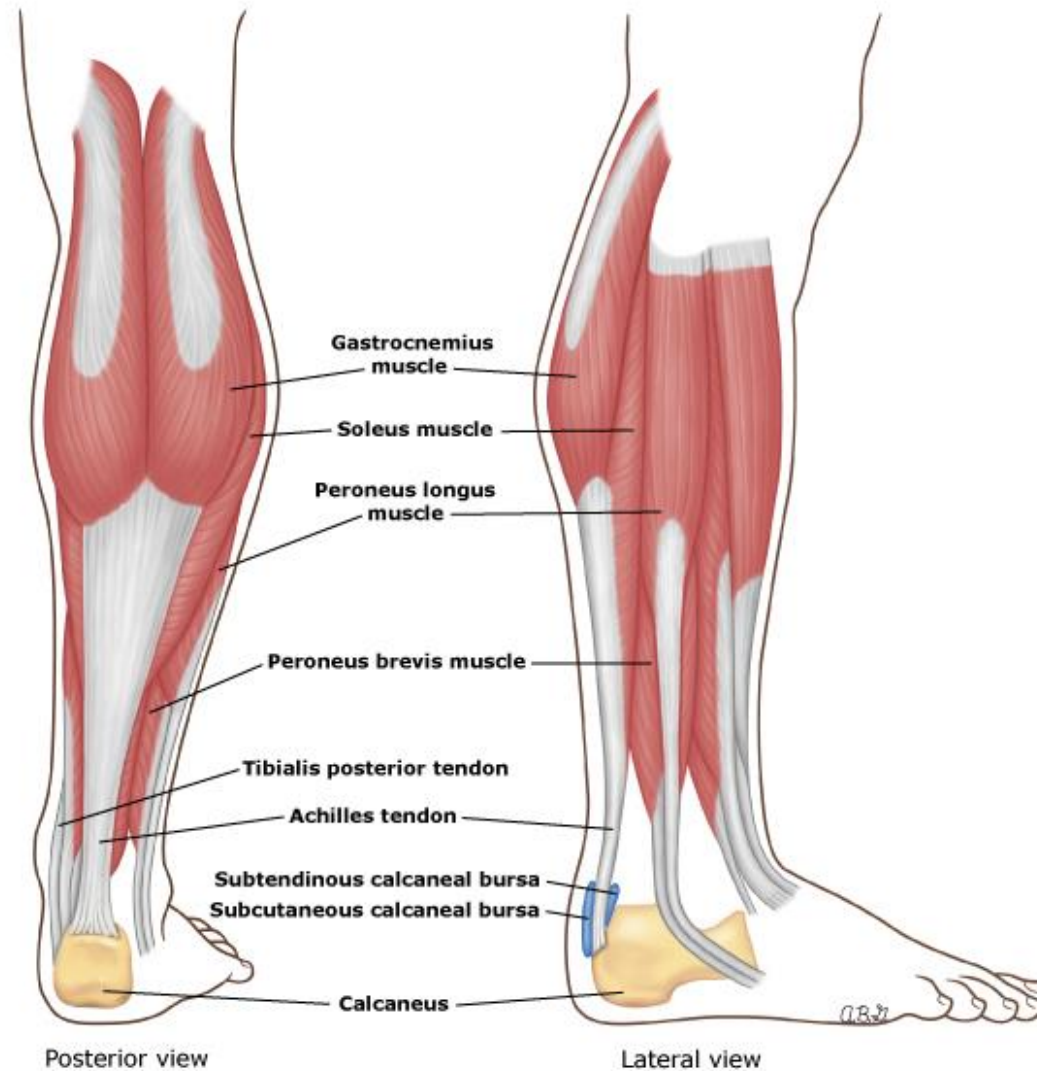
Lien Anatomie

Cet algorithme décisionnel ne se substitue pas au jugement clinique.



## Anatomy of the Achilles tendon and superficial posterior calf muscles

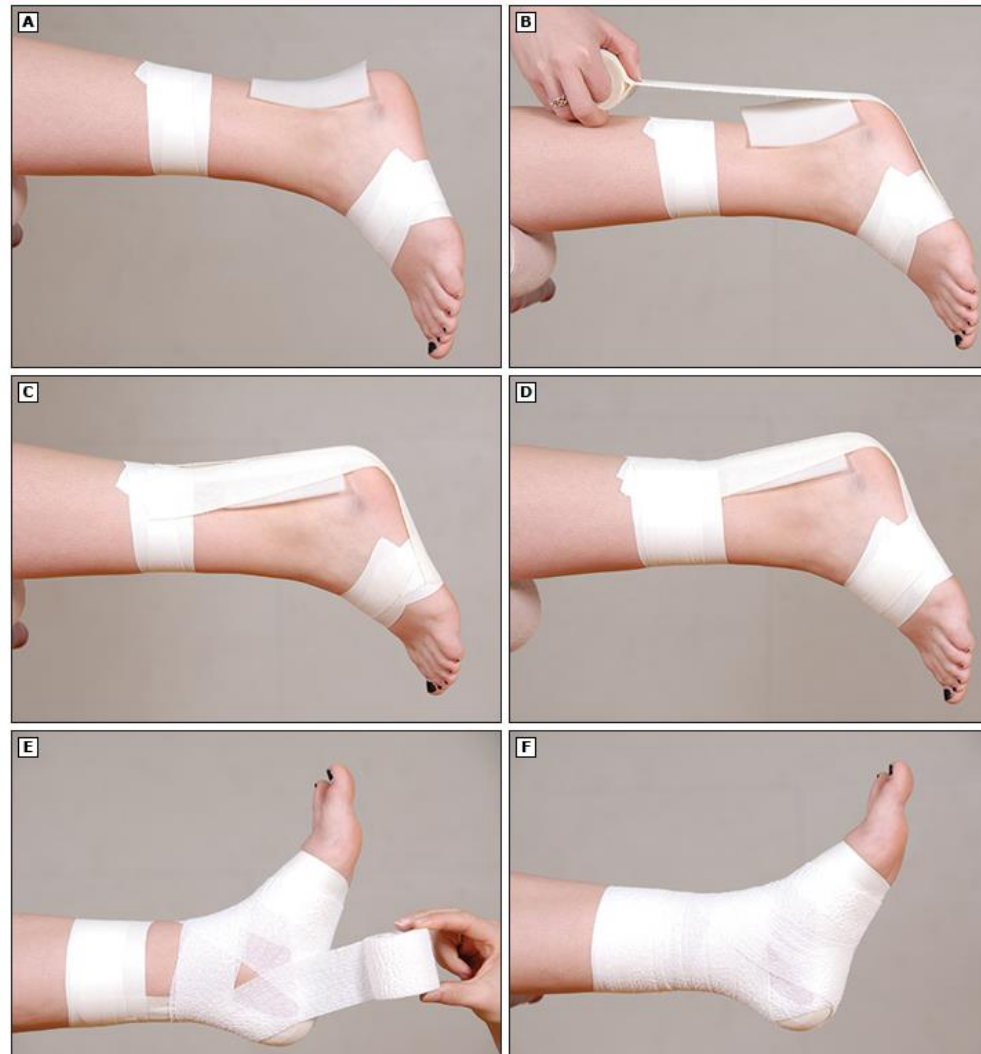Retour tendon  
d'achille



Note that the subtendinous bursa is also referred to as the retrocalcaneal bursa.

## Achilles tendon taping

Retour tendon  
d'achille



Athletes or others recovering from an Achilles tendon strain may benefit from additional support, such as that described here, while resuming activity:

(A) Apply anchors.

(B) Apply three to five strips in an X pattern from distal to proximal anchor.

(C) Check that dorsiflexion is appropriately limited (ie, does not extend to range that provokes pain).

(D) Re-anchor the X distally and proximally.

(E-F) Apply a figure eight and heel locks.

Reproduced with permission from: Anderson MK, Parr GP. *Foundations of Athletic Training: Prevention, Assessment, and Management*, 5th ed, Lippincott Williams & Wilkins, Philadelphia 2013. Copyright © 2013 Lippincott Williams & Wilkins.

[www.lww.com](http://www.lww.com).

Retour tendon  
d'achille

